

ONCOLOGY

The role of the fallopian tube in the origin of ovarian cancer

Britt K. Erickson, MD; Michael G. Conner, MD; Charles N. Landen Jr, MD

At the core of understanding any malignancy is determining exactly where the tumor originates. Determination of the cells of origin helps researchers better understand carcinogenesis and subsequently has implications for diagnosing, classifying, treating, and preventing malignancies.

For many epithelial malignancies, the cell of origin is well defined with precursor lesions easily identified. For example, adenocarcinoma of the colon originates in dysplastic lesions within the colonic mucosa, and cervical cancer originates from human papillomavirus (HPV)-infected cells in the cervical transformation zone.^{1,2} In contrast to these tumor types, the origins of epithelial ovarian cancer (EOC) are not clearly defined. Moreover, primary peritoneal cancer and primary tubal cancer are typically grouped with EOC despite apparently distinct anatomic locations.

Many theories have been proposed as to the cells of origin and mechanisms of carcinogenesis of ovarian cancer.

From the Divisions of Gynecologic Oncology (Drs Erickson and Landen) and Anatomic Pathology (Dr Conner), University of Alabama at Birmingham, Birmingham, AL.

Received Feb. 14, 2013; revised April 2, 2013; accepted April 8, 2013.

Supported in part by T32-CA091078 (Dr Erickson), and by the University of Alabama at Birmingham Center for Clinical and Translational Science (5UL1RR025777); the Reproductive Scientist Development Program through the Ovarian Cancer Research Fund and the National Institutes of Health (K12 HD00849); and the Department of Defense Ovarian Cancer Research Academy (OC093443) (Dr Landen).

The authors report no conflict of interest.

Reprints: Charles N. Landen Jr, MD, Division of Gynecologic Oncology, University of Alabama at Birmingham, 176F Suite 10250, 619 19 St. S., Birmingham, AL 35294. clanden@uabmc.edu.

0002-9378/\$36.00

© 2013 Mosby, Inc. All rights reserved.

<http://dx.doi.org/10.1016/j.ajog.2013.04.019>

Advanced cases of epithelial ovarian, primary peritoneal, and primary tubal malignancies have a relatively poor prognosis and collectively remain the most deadly of all gynecologic malignancies. Although traditionally thought of as one disease process, ongoing research suggests that there is not 1 single site or cell type from which these cancers arise. A majority of the serous tumors appear to originate from dysplastic lesions in the distal fallopian tube. Therefore, what we have traditionally considered "ovarian" cancer may in fact be tubal in origin. In this article, we will review epithelial ovarian cancer classification and genetics, theories regarding cells of origin with a focus on tubal intraepithelial carcinoma, and implications for prevention and screening.

Key words: ovarian carcinogenesis, TP53 mutation, tubal intraepithelial carcinoma

Traditionally based on epidemiologic studies and pathologic observation, these theories largely assumed that EOC was one disease process. As technology has improved and more sophisticated molecular techniques have developed, we now understand EOC to be a complex and heterogeneous disease process.

Just as endometriosis has been implicated in the development of some endometrioid ovarian adenocarcinomas,³ emerging data suggest that the fallopian tube may play a critical role in the origin of what has traditionally been classified as serous ovarian cancer. In this review we will discuss proposed mechanisms of "ovarian" carcinogenesis focusing on the emerging role of the fallopian tube in the development of ovarian cancer.

Ovarian cancer classification and genetics

Ovarian cancer is the most lethal gynecologic malignancy. In 2013, it is estimated there will be >22,000 new diagnoses and >14,000 deaths from the disease.⁴ Although many improvements have been made in surgical techniques and adjuvant treatment, the prognosis of ovarian cancer is poor, with a 5-year survival rate of only 45%.⁵ The majority of ovarian cancer is diagnosed in advanced stages, in part because no screening test exists to detect preinvasive or early-stage disease.

Traditionally, EOC is divided into its histologic subtypes: serous, mucinous, endometrioid, clear cell, transitional cell, or any combination of these (mixed). Serous histology is the most common, representing 70% of EOC.⁶ Serous tumors are aggressive tumors that usually present at an advanced stage, and although they commonly respond to surgery and platinum-based chemotherapy, they usually recur.

With improved molecular techniques, it has recently been shown that almost all of these serous tumors harbor TP53 mutations.⁷ In fact, serous EOC has the highest frequency of TP53 mutations of any solid cancer.⁷ These high-grade, clinically aggressive TP53-mutated serous cancers are now often termed "type 2" EOC.⁸ In contrast to type 2 tumors, type 1 tumors often present at earlier stages, have a more indolent clinical course, and rarely have TP53 mutations. Instead, they carry other genetic mutations suggesting distinct pathways of carcinogenesis including phosphatase and tensin homolog (PTEN), v-Ki-ras2 Kirsten rat sarcoma viral oncogene homology (KRAS), and v-raf murine sarcoma viral oncogene homolog B1 (BRAF).^{9,10} Although the terminology suggests that low-grade and high-grade EOC may be a spectrum of disease, it is now believed that these represent 2 distinct pathologic entities with different origins, mutations, behavior, and clinical course.^{11,12}

Cellular composition of the ovary

The ovary is derived from multiple embryonic structures including the coelomic epithelium, the subcoelomic mesoderm, and the primordial germ cells from the yolk sac endoderm. The rest of the female genital tract, including the fallopian tubes, uterus, cervix, and upper vagina, are derived from the Müllerian ducts. These distinctly different developmental pathways are highlighted by the fact that in patients with müllerian agenesis, the ovaries are usually functional and intact.

As a result of its complex embryologic development, the ovary is composed of various cell types that serve specific structural, hormonal, or reproductive functions. Additionally, each cell type can develop into a distinctly different neoplasm. For example, granulosa cell tumors and fibrothecomas develop from stromal cells, and teratomas and yolk sac tumors originate from germ cells. EOC is frequently thought of in the same manner. However, the ovary does not actually contain a well-differentiated epithelium. Instead, the ovary is covered with a single-cell mesothelial layer, termed the "ovarian surface epithelium" (OSE). This layer derives from the coelomic epithelium, not the Müllerian ducts, and also covers the serosa of the fallopian tubes, uterus, and peritoneal cavity. The cells of the OSE are distinct from other differentiated epithelial layers from a molecular standpoint as well. OSE does not express cancer antigen 125 (CA125) or E-cadherin, which are markers of mature, differentiated epithelium.¹³ Instead, OSE expresses the mesenchymal markers vimentin and N-cadherin.¹⁴

So then, why are these malignancies termed "epithelial," if no true well-differentiated ovarian epithelium exists? On pathologic assessment, these cancers are composed of elements that resemble, both in histology and genetic mutations, Müllerian-derived epithelium of the female genital tract. Specifically, serous tumors resemble the cells found in the tubal epithelium, mucinous tumors resemble the mucin-producing glandular cells of the endocervix, and endometrioid tumors resemble the structure of the endometrium.¹⁵

Theories of origin of EOC

Early attempts to characterize ovarian carcinogenesis noted a clear relationship between ovulation and risk for ovarian cancer. In 1971, Fathalla¹⁶ first described the incessant ovulation hypothesis. In these studies performed on hens, a high rate of metastatic ovarian adenocarcinoma was noted in the hens that were forced to produce an excessive number of eggs without any breaks in ovulation. It was theorized that OSE cells are damaged during the process of ovulation and then internalized to form cortical inclusion cysts.¹⁶ It was postulated that these cysts then undergo metaplasia to become differentiated Müllerian-like epithelium, eventually becoming dysplastic, and ultimately leading to ovarian carcinoma.¹⁷ This transformation may result from constant exposure to growth factors secreted into the cyst that normally would be lost into the peritoneal cavity when secreted by cells on the ovarian surface.

This theory is further supported by epidemiologic evidence in human beings showing an association between ovulation and an increased risk for ovarian cancer.¹⁸ Women who have breaks in ovulation due to pregnancy and breastfeeding have lower risk of disease.^{19,20} Moreover, women who take oral contraceptive pills (OCPs), and therefore have fewer ovulatory cycles, reduce their risk of ovarian cancer by almost 50%.^{21,22}

Not all epidemiologic evidence supports the hypothesis that incessant ovulation is the culprit for tumor initiation. For example, women with polycystic ovarian syndrome, who by default ovulate infrequently, are at increased risk for EOC.²³ Although it was initially proposed that OCP use decreased the risk of ovarian cancer by decreasing the number of ovulatory cycles, it appears that the protective effect of OCPs is similar in progesterone-only formulations, which usually do not inhibit ovulation.²⁴

Due in some part to the weaknesses identified in the incessant ovulation hypothesis, another theory was proposed regarding how OSE transforms into malignancy. The gonadotropin hypothesis theorizes that overstimulation of

OSE via follicle stimulating hormone (FSH) and luteinizing hormone (LH) receptors leads to proliferation and risk for malignant transformation.²⁵ Pregnant women and women taking OCPs also maintain lower levels of gonadotropins, potentially explaining their decreased risk of EOC. This could also explain the increased risk of EOC in nulliparous women, women with polycystic ovary syndrome, and women with other types of primary infertility who also have increased gonadotropin production. The increased production of gonadotropins in perimenopausal women may also account for the increase in incidence of EOC presenting approximately 10 years after menopause. However, despite these theories, serum FSH and LH levels have not correlated with risk of disease in either premenopausal or postmenopausal women.^{26,27} Moreover, although animal studies have shown that gonadotropin exposure promotes tumor growth, no study has been able to convincingly demonstrate malignant transformation of OSE or cortical inclusion cysts with gonadotropin exposure.⁹

Although these and other theories have been proposed to describe how the ovarian mesothelium could undergo metaplasia and dysplasia,^{28,29} perhaps the greatest gap in understanding the process of ovarian carcinogenesis from OSE is the identification of a true precursor lesion of high-grade carcinoma within the ovary. Although benign ovarian cystadenomas can progress into a borderline tumor (and later a low-grade malignancy), the progression of low-grade to high-grade serous carcinoma is exceedingly rare.³⁰ Ovarian endometriosis has been identified within endometrioid and some mixed histology ovarian cancers, however it does not seem to be causative in serous tumors.³¹

In search of a cell of origin

As the complexity and heterogeneity of the origins of ovarian cancer became apparent, it was clear that there is likely not 1 single location or etiology for all types of EOC. For example, endometriosis became more definitively linked to many cases of endometrioid and clear cell EOC. Mucinous tumors were recognized

as often coming from appendiceal or other gastrointestinal origins. Thus the search to identify a precursor lesion of high-grade serous carcinoma intensified.

In 2001, Piek et al³² reported close examination of tubal segments removed from women undergoing a risk-reducing bilateral salpingo-oophorectomy (BSO). These women had either breast cancer gene (BRCA) mutations or a strong family history of ovarian cancer. Of 12 pathologic specimens examined, 6 had areas of cellular dysplasia noted in the tubal epithelium and 5 additional specimens had hyperplastic lesions. These hyperplastic and dysplastic lesions histologically resembled high-grade serous ovarian cancer, but without invasion.

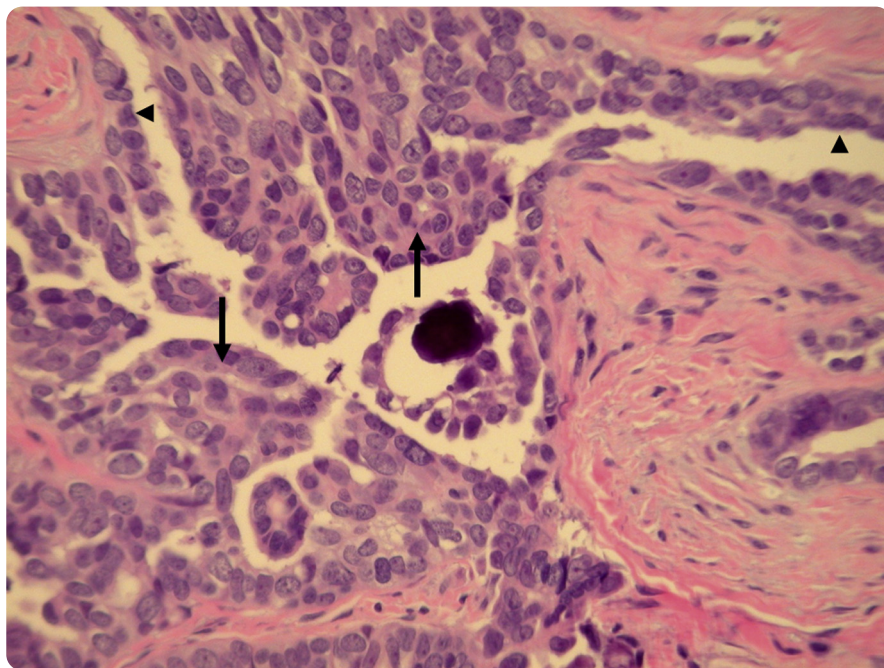
When larger cohorts of patients with BRCA mutations were studied with thin sectioning and careful analysis of the fallopian tube, it was noted that about 1-5% of patients already had an early tubal malignancy at the time of their risk-reducing surgery.^{33,34} The majority of these malignancies had an early intraepithelial component and they all were located in the distal fimbriated end of the fallopian tube. As a result of the detection of occult malignancies and dysplastic lesions, it appeared that these patients had a higher risk for serous carcinoma derived from the fallopian tube, not the ovary.³⁵ Fallopian tube carcinoma thus became part of the spectrum of BRCA-associated diseases.^{32,35}

In 2003, in a letter to the editor, Piek et al³⁶ synthesized these data and proposed a new hypothesis regarding the relationship between tubal and ovarian serous carcinoma. They hypothesized that most hereditary serous carcinomas originate from the epithelium of the fallopian tube. These tubal epithelial cells are then spilled onto the surface of the ovary and therefore create the appearance of ovarian origin.

Regions of dysplasia within tubal epithelium were termed “tubal intraepithelial carcinoma” (TIC) and in most cases, these areas demonstrated high levels of p53 accumulation (Figure). As noted previously, TP53 mutations are present in almost 100% of type 2 high-grade serous ovarian cancers. The majority of TP53 mutations lead to the

FIGURE

Tubal intraepithelial carcinoma



Section of fallopian tube exhibiting tubal intraepithelial carcinoma (arrows) and adjacent normal tubal epithelium (arrowheads). Note lack of stromal invasion ($\times 200$).

Erickson. Fallopian tube in ovarian cancer. *Am J Obstet Gynecol* 2013.

production of a nonfunctional p53 protein that accumulates in the cytoplasm of tumor cells. Thus, positive p53 staining is a surrogate for TP53 mutational status. Subsequent studies in patients with BRCA mutations have shown that even “benign” areas of distal tubal epithelium overexpress p53. These areas are termed “p53 signatures”³⁷ and may represent an even earlier precursor lesion than TIC in the development of high-grade serous carcinomas. The fact that TIC often stains p53 positive and contains such a signature further suggests premalignant changes at the molecular level.^{32,38}

Beyond BRCA mutation carriers

These patterns of tumor origin were next studied outside of cohorts of BRCA mutation carriers. Kindelberger et al³⁹ examined the pathology of 55 women with advanced-stage cases of serous ovarian, tubal, or primary peritoneal carcinoma. Tubal specimens were subjected to careful thin sectioning of the fimbriae as well as p53 immunostaining.

Surprisingly, 75% of all cases of pelvic serous carcinomas contained areas of TIC. Specifically, 5 of 5 cases of tubal carcinomas contained TIC, 4 of 6 peritoneal carcinomas, and 20 of 30 ovarian carcinomas. The majority (93%) of TIC was identified in the distal tubal fimbriae. In the cases where TIC was identified in a patient with ovarian carcinoma, most ovarian tumors were both bilateral and also intraparenchymal.

These areas of TIC were dissected and subject to p53 immunostaining and specific TP53 mutational analysis. Thousands of distinct TP53 mutations have been described in human cancers and thus a tumor’s TP53 mutation can serve as its unique label.⁴⁰ In all 5 cases subject to TP53 mutational analysis, the exact same TP53 mutation that was identified in the TIC was identified in the metastatic ovarian tumor, supporting their clonality. Therefore, although the distal fallopian tube cannot be implicated universally in the development of carcinoma, as was suggested in

BRCA mutation carriers, its frequent involvement in what has typically been termed “ovarian” cancer has changed our understanding of the cells of origin of EOC and has prompted further research.

In another large pathological assessment of 52 cases of EOC, Przybycin et al⁴¹ noted a TIC frequency rate of 59% in patients with serous tumors. They also noted that there was no TIC identified in mucinous, endometrioid, or carcinosarcoma histologies.⁴¹ Thus TIC seems to be uniquely associated with the development of serous histology EOC. Kuhn et al⁴² further showed the clonality of TIC and the metastatic counterparts in a study that examined the histology of 29 patients with both TIC and high-grade serous tumors. In all, 93% of the paired specimens had identical TP53 mutations in the TIC and metastatic tumor, providing further evidence that these areas of TIC are the precursor lesions for the metastatic tumor.

Unifying the hypotheses

It is clear that TIC is not present in every case of high-grade serous ovarian cancer. Therefore, a dual pathway model for the carcinogenesis of high-grade pelvic serous tumors has been proposed. As evidenced by studies identifying the clonal relationship between TIC and metastatic tumor, the majority of serous tumors likely originate in the distal fallopian tube. These small areas of dysplasia eventually become malignant and, due to their location, metastasize to the ovaries and surrounding pelvic structures. They may also present as fallopian tube cancers or primary peritoneal cancer if there is no significant involvement of the ovary. The remaining cases of serous EOC may have truly ovarian origins. Müllerian epithelium, present on the ovary through either metaplasia of the ovarian mesothelium or ectopic Müllerian tissue (eg, endometriosis and endosalpingiosis) could progress to dysplastic epithelium and eventually lead to malignant transformation.

The role of the fallopian tube in other histologic types of EOC is also being investigated. Based on the areas of

papillary tubal hyperplasia noted in patients with low-grade serous tumors, it is hypothesized that these ovarian and extraovarian tumors may also have precursor lesions in the fallopian tube.⁴³ Moreover, with further study of the ovarian mesothelium and ovarian inclusion cysts, it appears that even inclusion cysts may have fallopian tube origins.⁴³

Implications for prevention

Effective cancer screening programs typically require identification of either a precursor lesion or an early-stage malignancy. This is demonstrated most notably in colon, cervix, and breast cancer screening. Unfortunately, without a clear precursor lesion or biomarker, ovarian cancer screening has thus far been unsuccessful in identifying preinvasive or early-stage disease. A large trial studying ultrasonography and serum CA125 for ovarian cancer screening in asymptomatic women was unable to demonstrate efficacy in detecting early-stage disease.⁴⁴ Modifications to this approach may demonstrate efficacy, either by following CA125 over time rather than at a single point,⁴⁵ or by triaging patients to ultrasound only if the CA125 is consistently elevated.⁴⁶ Because the majority of EOC precursor lesions are not harbored within the ovary, it is not surprising that adnexal imaging is of limited utility.

Although no method of TIC detection has been established short of surgical resection, the future holds promise for novel methods of EOC screening and prevention. Models have predicted that TIC and early-stage disease are likely present for at least 4 years before becoming widely metastatic.⁴⁷ With improved understanding of TIC and its role in carcinogenesis, there may be opportunities for developing screening methods and biomarker identification.⁴⁸⁻⁵¹

Due to the role of the fallopian tube in EOC, approaches to gynecologic surgery have already begun to shift. Risk-reducing surgery for patients with BRCA mutations currently includes complete excision of the ovaries and fallopian tubes with serial sectioning. With careful excision and close evaluation, rates of occult

preinvasive or invasive tubal malignancies in this population may be as high as 10%.⁵²

Surgical implications may extend beyond prophylactic surgery for high-risk patients. In the United States, >600,000 hysterectomies are performed each year and about 55% of hysterectomies are accompanied by BSO.⁵³ There has been considerable debate about the risks and benefits of performing a BSO at the time of hysterectomy. On one hand, the risk of EOC is reduced, but this comes at the expense of the potential risks of cardiovascular disease, osteoporosis, and even cognitive impairment seen with early surgical menopause.⁵⁴ In a large analysis of >20,000 patients from the Nurses' Health Study, all-cause mortality as well as cancer mortality both increased in women who received a BSO.⁵⁵ This was due primarily to increases in heart disease and stroke. The authors concluded that with an expected lifespan of 35 years after surgery, for every 9 BSOs performed there was 1 additional early death.⁵⁵

With the risks associated with BSO at the time of hysterectomy for benign disease, it is becoming more apparent that it may be clinically prudent to leave the ovaries in place for prolonged hormone exposure. However, because the post-reproductive fallopian tube serves little biologic purpose, it may be sensible to perform *only* a salpingectomy at the time of surgery. Although no prospective data support this practice, it follows rationally that this has the potential to reduce the risk of serous carcinoma with little or no increased morbidity.⁵⁶ Given that an estimated 80-90% of BRCA-related “ovarian” cancers originate in the fallopian tube, consideration might also be given to performing a risk-reducing salpingectomy in especially young patients.⁵⁷

It has long been noted that bilateral tubal ligation confers some protection toward developing ovarian cancer. Specifically, in a metaanalysis of 13 studies, there was a 34% risk reduction in the development of endometrioid and serous EOC.⁵⁸ Proposed mechanisms include effects on ovarian function and mechanical barriers against ascending vaginal carcinogens and ascending proximal tubal or endometrial cells.⁵⁹

Due to their localization at the fimbriated end of the fallopian tube, it is unlikely that tubal ligation surgically removes areas of TIC, however this has not yet been rigorously evaluated.

Finally, there may be opportunities to sample the fallopian tube for preinvasive disease. Kinde et al⁶⁰ reported that TP53 mutations can be detected in cervical cytology specimens in 40% of ovarian cancers. Protocols are being evaluated whereby the fallopian epithelial cells are brushed away hysteroscopically for cytologic analysis.

Conclusion

Epithelial ovarian, primary peritoneal, and primary tubal malignancies are a complex and heterogeneous group of tumors that remain the most deadly of all gynecologic malignancies. Ongoing research has confirmed that there is not 1 single site or cell type from which these cancers arise. A majority of serous carcinomas appear to have preinvasive lesions in the distal fallopian tube. This recent finding has shifted the paradigm of ovarian cancer carcinogenesis. Complete bilateral salpingectomy as a risk-reducing strategy in patients with BRCA mutations is an approach worthy of further investigation and it may be reasonable to consider salpingectomy for all patients undergoing hysterectomy for benign disease. As we move forward, new research directed specifically at TIC may provide insight into carcinogenesis, and molecular studies may someday allow for more effective screening strategies. ■

REFERENCES

1. Winawer SJ, Zauber AG, Fletcher RH, et al. Guidelines for colonoscopy surveillance after polypectomy: a consensus update by the US Multi-Society Task Force on Colorectal Cancer and the American Cancer Society. *CA Cancer J Clin* 2006;56:143-59; quiz 184-5.
2. Pudney J, Quayle AJ, Anderson DJ. Immunological microenvironments in the human vagina and cervix: mediators of cellular immunity are concentrated in the cervical transformation zone. *Biol Reprod* 2005;73:1253-63.
3. Jiang X, Morland SJ, Hitchcock A, et al. Allelotyping of endometriosis with adjacent ovarian carcinoma reveals evidence of a common lineage. *Cancer Res* 1998;58:1707-12.

4. Siegel R, Naishadham D, Jemal A. Cancer statistics, 2013. *CA Cancer J Clin* 2013;63:11-30.
5. Siegel R, Ward E, Brawley O, et al. Cancer statistics, 2011: the impact of eliminating socioeconomic and racial disparities on premature cancer deaths. *CA Cancer J Clin* 2011;61:212-36.
6. McCluggage WG. Morphological subtypes of ovarian carcinoma: a review with emphasis on new developments and pathogenesis. *Pathology* 2011;43:420-32.
7. Ahmed AA, Etemadmoghadam D, Temple J, et al. Driver mutations in TP53 are ubiquitous in high grade serous carcinoma of the ovary. *J Pathol* 2010;221:49-56.
8. Shih leM, Kurman RJ. Ovarian tumorigenesis: a proposed model based on morphological and molecular genetic analysis. *Am J Pathol* 2004;164:1511-8.
9. Landen CN Jr, Birrer MJ, Sood AK. Early events in the pathogenesis of epithelial ovarian cancer. *J Clin Oncol* 2008;26:995-1005.
10. O'Neill CJ, Deavers MT, Malpica A, et al. An immunohistochemical comparison between low-grade and high-grade ovarian serous carcinomas: significantly higher expression of p53, MIB1, BCL2, HER-2/neu, and C-KIT in high-grade neoplasms. *Am J Surg Pathol* 2005;29:1034-41.
11. Singer G, Shih leM, Truskinovsky A, et al. Mutational analysis of K-ras segregates ovarian serous carcinomas into two types: invasive MPSC (low-grade tumor) and conventional serous carcinoma (high-grade tumor). *Int J Gynecol Pathol* 2003;22:37-41.
12. Singer G, Stohr R, Cope L, et al. Patterns of p53 mutations separate ovarian serous borderline tumors and low- and high-grade carcinomas and provide support for a new model of ovarian carcinogenesis: a mutational analysis with immunohistochemical correlation. *Am J Surg Pathol* 2005;29:218-24.
13. Sundfeldt K, Piontkewitz Y, Ivarsson K, et al. E-cadherin expression in human epithelial ovarian cancer and normal ovary. *Int J Cancer* 1997;74:275-80.
14. Blaustein A. Peritoneal mesothelium and ovarian surface cells—shared characteristics. *Int J Gynecol Pathol* 1984;3:361-75.
15. Marquez RT, Baggerly KA, Patterson AP, et al. Patterns of gene expression in different histotypes of epithelial ovarian cancer correlate with those in normal fallopian tube, endometrium, and colon. *Clin Cancer Res* 2005;11:6116-26.
16. Fathalla MF. Incessant ovulation—a factor in ovarian neoplasia? *Lancet* 1971;2:163.
17. Auersperg N, Wong AS, Choi KC, et al. Ovarian surface epithelium: biology, endocrinology, and pathology. *Endocr Rev* 2001;22:255-88.
18. Casagrande JT, Louie EW, Pike MC, et al. "Incessant ovulation" and ovarian cancer. *Lancet* 1979;2:170-3.
19. Soegaard M, Jensen A, Hogdall E, et al. Different risk factor profiles for mucinous and

nonmucinous ovarian cancer: results from the Danish MALOVA study. *Cancer Epidemiol Biomarkers Prev* 2007;16:1160-6.

20. Rosenblatt KA, Thomas DB. Lactation and the risk of epithelial ovarian cancer: the WHO collaborative study of neoplasia and steroid contraceptives. *Int J Epidemiol* 1993;22:192-7.
21. Cramer DW, Hutchison GB, Welch WR, et al. Factors affecting the association of oral contraceptives and ovarian cancer. *N Engl J Med* 1982;307:1047-51.
22. Epithelial ovarian cancer and combined oral contraceptives: the WHO collaborative study of neoplasia and steroid contraceptives. *Int J Epidemiol* 1989;18:538-45.
23. Schildkraut JM, Schwingl PJ, Bastos E, et al. Epithelial ovarian cancer risk among women with polycystic ovary syndrome. *Obstet Gynecol* 1996;88:554-9.
24. Rosenberg L, Palmer JR, Zauber AG, et al. A case-control study of oral contraceptive use and invasive epithelial ovarian cancer. *Am J Epidemiol* 1994;139:654-61.
25. Cramer DW, Welch WR. Determinants of ovarian cancer risk, II: inferences regarding pathogenesis. *J Natl Cancer Inst* 1983;71:717-21.
26. Arslan AA, Zeleniuch-Jacquotte A, Lundin E, et al. Serum follicle-stimulating hormone and risk of epithelial ovarian cancer in postmenopausal women. *Cancer Epidemiol Biomarkers Prev* 2003;12:1531-5.
27. Helzlsouer KJ, Alberg AJ, Gordon GB, et al. Serum gonadotropins and steroid hormones and the development of ovarian cancer. *JAMA* 1995;274:1926-30.
28. Risch HA. Hormonal etiology of epithelial ovarian cancer, with a hypothesis concerning the role of androgens and progesterone. *J Natl Cancer Inst* 1998;90:1774-86.
29. Ness RB, Cottreau C. Possible role of ovarian epithelial inflammation in ovarian cancer. *J Natl Cancer Inst* 1999;91:1459-67.
30. Boyd C, McCluggage WG. Low-grade ovarian serous neoplasms (low-grade serous carcinoma and serous borderline tumor) associated with high-grade serous carcinoma or undifferentiated carcinoma: report of a series of cases of an unusual phenomenon. *Am J Surg Pathol* 2012;36:368-75.
31. Oral E, Ilvan S, Tustas E, et al. Prevalence of endometriosis in malignant epithelial ovary tumors. *Eur J Obstet Gynecol Reprod Biol* 2003;109:97-101.
32. Piek JM, van Diest PJ, Zweemer RP, et al. Dysplastic changes in prophylactically removed fallopian tubes of women predisposed to developing ovarian cancer. *J Pathol* 2001;195:451-6.
33. Callahan MJ, Crum CP, Medeiros F, et al. Primary fallopian tube malignancies in BRCA-positive women undergoing surgery for ovarian cancer risk reduction. *J Clin Oncol* 2007;25:3985-90.
34. Cass I, Holschneider C, Datta N, et al. BRCA-mutation-associated fallopian tube

carcinoma: a distinct clinical phenotype? *Obstet Gynecol* 2005;106:1327-34.

35. Leeper K, Garcia R, Swisher E, et al. Pathologic findings in prophylactic oophorectomy specimens in high-risk women. *Gynecol Oncol* 2002;87:52-6.

36. Piek JM, Verheijen RH, Kenemans P, et al. BRCA1/2-related ovarian cancers are of tubal origin: a hypothesis. *Gynecol Oncol* 2003;90:491.

37. Lee Y, Miron A, Drapkin R, et al. A candidate precursor to serous carcinoma that originates in the distal fallopian tube. *J Pathol* 2007;211:26-35.

38. Lee Y, Medeiros F, Kindelberger D, et al. Advances in the recognition of tubal intraepithelial carcinoma: applications to cancer screening and the pathogenesis of ovarian cancer. *Adv Anat Pathol* 2006;13:1-7.

39. Kindelberger DW, Lee Y, Miron A, et al. Intraepithelial carcinoma of the fimbria and pelvic serous carcinoma: evidence for a causal relationship. *Am J Surg Pathol* 2007;31:161-9.

40. Soussi T, Ishioka C, Claustres M, et al. Locus-specific mutation databases: pitfalls and good practice based on the p53 experience. *Nat Rev Cancer* 2006;6:83-90.

41. Przybycin CG, Kurman RJ, Ronnett BM, et al. Are all pelvic (nonuterine) serous carcinomas of tubal origin? *Am J Surg Pathol* 2010;34:1407-16.

42. Kuhn E, Kurman RJ, Vang R, et al. TP53 mutations in serous tubal intraepithelial carcinoma and concurrent pelvic high-grade serous carcinoma—evidence supporting the clonal relationship of the two lesions. *J Pathol* 2012;226:421-6.

43. Kurman RJ, Vang R, Junge J, et al. Papillary tubal hyperplasia: the putative precursor of ovarian atypical proliferative (borderline) serous tumors, noninvasive implants, and

endosalpingiosis. *Am J Surg Pathol* 2011;35:1605-14.

44. Buys SS, Partridge E, Black A, et al. Effect of screening on ovarian cancer mortality: the prostate, lung, colorectal and ovarian (PLCO) cancer screening randomized controlled trial. *JAMA* 2011;305:2295-303.

45. Drescher CW, Shah C, Thorpe J, et al. Longitudinal screening algorithm that incorporates change over time in CA125 levels identifies ovarian cancer earlier than a single-threshold rule. *J Clin Oncol* 2013;31:387-92.

46. Menon U, Gentry-Maharaj A, Hallett R, et al. Sensitivity and specificity of multimodal and ultrasound screening for ovarian cancer, and stage distribution of detected cancers: results of the prevalence screen of the UK collaborative trial of ovarian cancer screening (UKCTOCS). *Lancet Oncol* 2009;10:327-40.

47. Brown PO, Palmer C. The preclinical natural history of serous ovarian cancer: defining the target for early detection. *PLoS Med* 2009;6:e1000114.

48. Kuhn E, Kurman RJ, Sehdev AS, et al. Ki-67 labeling index as an adjunct in the diagnosis of serous tubal intraepithelial carcinoma. *Int J Gynecol Pathol* 2012;31:416-22.

49. Kuhn E, Kurman RJ, Soslow RA, et al. The diagnostic and biological implications of laminin expression in serous tubal intraepithelial carcinoma. *Am J Surg Pathol* 2012;36:1826-34.

50. Crum CP, McKeon FD, Xian W. The oviduct and ovarian cancer: causality, clinical implications, and “targeted prevention.” *Clin Obstet Gynecol* 2012;55:24-35

51. Chivukula M, Niemeier LA, Edwards R, et al. Carcinomas of distal fallopian tube and their association with tubal intraepithelial carcinoma: do they share a common “precursor” lesion? loss of heterozygosity and immunohistochemical

analysis using PAX 2, WT-1, and P53 markers. *ISRN Obstet Gynecol* 2011;2011:858647.

52. Powell CB, Kenley E, Chen LM, et al. Risk-reducing salpingo-oophorectomy in BRCA mutation carriers: role of serial sectioning in the detection of occult malignancy. *J Clin Oncol* 2005;23:127-32.

53. Whiteman MK, Hillis SD, Jamieson DJ, et al. Inpatient hysterectomy surveillance in the United States, 2000-2004. *Am J Obstet Gynecol* 2008;198:34e1-7.

54. Shuster LT, Gostout BS, Grossardt BR, et al. Prophylactic oophorectomy in premenopausal women and long-term health. *Menopause Int* 2008;14:111-6.

55. Parker WH, Broder MS, Chang E, et al. Ovarian conservation at the time of hysterectomy and long-term health outcomes in the nurses’ health study. *Obstet Gynecol* 2009;113:1027-37.

56. Dietl J, Wischhusen J, Hausler SF. The post-reproductive fallopian tube: better removed? *Hum Reprod* 2011;26:2918-24.

57. Kwon JS, Tinker A, Pansegrau G, et al. Prophylactic salpingectomy and delayed oophorectomy as an alternative for BRCA mutation carriers. *Obstet Gynecol* 2013;121:14-24.

58. Cibula D, Widschwendter M, Majek O, et al. Tubal ligation and the risk of ovarian cancer: review and meta-analysis. *Hum Reprod Update* 2011;17:55-67.

59. Cibula D, Widschwendter M, Zikan M, et al. Underlying mechanisms of ovarian cancer risk reduction after tubal ligation. *Acta Obstet Gynecol Scand* 2011;90:559-63.

60. Kinde I, Bettgowda C, Wang Y, et al. Evaluation of DNA from the Papanicolaou test to detect ovarian and endometrial cancers. *Sci Transl Med* 2013;5:167ra4.